Viora's ReFit Solution

Skin Tightening and Body Contouring After Extreme Weight Loss

Inna Belenky (Ph.D.), Ariel Margulis (M.D., M.Sc.)
Viora Facility
Key words: Radiofrequency, RF energy, vacuum, skin tightening, body contouring, loose skin, redundant skin, stretch marks

ABSTRACT: Excessive weight loss, and fluctuations in fat volume, whether accomplished via diet and exercise, surgical and aesthetic procedures or post-pregnancy, can result in massive folds of redundant skin and stretch marks. Body contouring surgery has risks and complications, therefore, non-invasive body-contouring treatments are becoming more popular, including radiofrequency (RF)-based devices. In December 2010, Viora started treating E., a 27-year old male, with excess skin and stretch marks on the abdomen area, due to more than 50 Kg weight loss over a period of approximately 12 months. This young man was searching for skin tightening treatments in order to improve the appearance of his skin and improve his body image. The patient underwent ReFit™ treatments with a specific protocol developed for such cases. After eight sessions, the patient's skin showed dramatic improvement in the laxity and reduction of redundant skin on the abdomen area. Also, there was notably significant improvement in stretch mark appearance. At the first follow up visit, the patient stated he was finally not embarrassed to go to the beach and that he would strongly recommend treatments with ReFit™ protocol. The special treatment protocol may also be applied to other cases of excessive weight lost, such as post-pregnancy and post-aesthetic procedures for fat reduction.

Introduction

Weight loss may be achieved by dieting and exercise, or by surgical and aesthetic intervention, such as liposuction or laser-lipolysis. Excessive and rapid weight loss or fluctuations in fat volume can result in massive folds of redundant skin and stretch marks. When weight is gained, the skin expands and re-modulates to accommodate the excess fat underneath. When the weight is then lost, the skin remains enlarged, leading to redundant skin and stretch marks. These symptoms are exacerbated when weight loss is rapid. Moreover, in the overweight population, collagen has been found to contain a high amount of cross-linked collagen, resulting from glycosylation (Light *et al.,* 2010). Therefore, body contouring treatments for patients after excessive weight loss can serve as both aesthetic and functional procedures. These procedures generally address redundant skin and unwieldy subcutaneous tissue which create an unattractive appearance and are the source of hygiene problems and skin irritation (Sinno et al., 2011).

Many patients seek body contouring treatments to improve body image and decrease irritations in the skin folds. As with any procedure, body contouring surgery has its own risks and complications, including infection, hematoma and seroma formation, deep vein thrombosis and pulmonary embolism. It is still debated whether the long-term benefits that patients receive from invasive body contouring procedures are worth the increased risks involved in such surgeries (Sinno et al., 2011). Therefore, non-invasive body-contouring treatments are becoming more popular, due to their simplicity, safety and quick recovery rate. In addition, the non-invasive treatments for body contouring do not involve local anesthesia or any extensive pre/post preparations.

Non-invasive radiofrequency (RF)-based devices have become common practice in plastic and dermatological fields as complementary surgical procedures in order to achieve an overall body contouring effect. RF effects are based on mild heating of the skin's underlying network of collagen and elastin fibers which can lead to collagen shrinkage (restoring its flexibility) and dermal thickening, thereby improving the skin's firmness and elasticity (Sadick and Makino, 2004). When collagen is heated, the heat-labile intra-molecular cross-links (between the triple helix polypeptides) are broken, and the protein undergoes a transition from a highly organized crystalline structure to a random, gel-like state (denaturation). The shrinkage occurs through the cumulative effect of the "unwinding" triple helix (as described above), and the residual tension of the heat-stable inter-molecular cross-links (Arnoczky and Aksan, 2000).

In December 2010, Viora started treating E., a 27-year old male, with excess skin and stretch marks on the abdomen area, due to weight loss of over 50 Kg of his body mass. This young man was searching for skin tightening treatments in order to improve the appearance of his skin. The main frustration for this patient was that even after losing a significant amount of weight, he was still dissatisfied with his body image.

Methods

Case Study

A 27 year old healthy male, who lost 52 Kg of his body mass over a period of approximately 12 months. The patient's height is 185 cm and his starting weight before dieting was 132 Kg (BMI=39). Upon his first visit to the Viora clinic, his weight was 80 Kg (BMI=24).

Device Description

Viora's bipolar RF system, utilizing unique CORE™ technology (Cohen and Bar-Yosef, 2009) that combines vacuum with multiple frequency capability. The system enables 4 vacuum intensities (up to 500 mbars) along with 4 RF power intensities (up to 50 Watts/ 130 J/cm 3). The system includes three treatment applicators: two applicators that utilize RF energy and vacuum for cellulite reduction, body contouring and circumferential reduction (BC applicator for treating large areas and FC applicator for sensitive areas) and one ST applicator utilizing high RF energy for skin tightening treatment of the face and body.

This unique CORE™ technology enables independent heating depth control by applying three distinct RF frequencies, 0.8 MHz (Mode I), 1.7 MHz (Mode II) and 2.45 MHz (Mode III), as well as a combination of all three frequencies (Mode IV) in a single pulse. One of the advantages of Mode IV is enabling the operator to heat all skin layers simultaneously.

Treatment Regimen

The patient underwent a treatment course of eight sessions with two weeks intervals. The treatment session consisted of a 20 minute special skin tightening treatment with the BC applicator over the abdomen area, and a further 10 minute treatment with the ST applicator over the stretch marks in the flanks area. The patient did not diet or induce any weight fluctuations above 2 Kg throughout the entire study period.

Clinical Assessment

Clinical photographic assessment was recorded in 4 phases: (1) at baseline - prior to the first treatment (2) during the treatment course - after the fourth treatment session (3) at the end of the treatment course - one week after the eighth treatment (4) at the one month follow-up visit, the patient's expectation and satisfaction assessments were taken at baseline and at the one month follow-up visit, respectively.

Additionally, the treating practitioners were asked to record and immediately report any adverse or unexpected side-effects.

© 2014 Viora Ltd.

Results

No adverse or unexpected side-effects were reported during the treatment course. Patient's weight remained constant at 80 Kg.

Figure 1 shows the dramatic improvement in the appearance of lax and redundant skin, with notable improvements in the abdomen area. Figure 2 shows the significant improvement in stretch mark appearance in the flanks area.

Before After

Figure 1: Before (left) and after 8 treatment sessions (right). Results show a noticeable improvement in lax, sagging skin in the abdomen area.

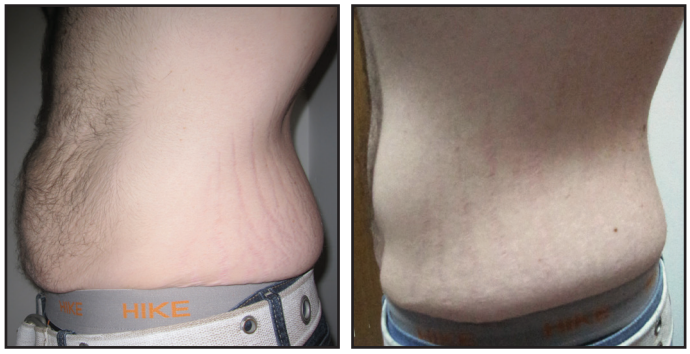

Before After

Figure 2: Before (left) and after 8 treatment sessions (right). Results show a noticeable improvement of sagging skin on the abdomen area and improvement of the stretch mark appearance on the flanks.

Patient's expectations at the beginning of the treatment course were to improve the quality and texture of his skin, by reducing the sagging appearance of his skin after his excessive weight loss. In addition, the patient hoped to improve his body image and feel more comfortable in his own skin. The patient had no expectations regarding improvement in the appearance of stretch marks. At his one month follow up visit, the patient filled out a satisfaction assessment form. According to his feedback, the results significantly exceeded his expectations. The patient claimed that he observed a dramatic improvement in his skin elasticity and the improvement in the appearance of his stretch marks was a pleasant surprise. At the first follow up visit (one month post completion of the treatment course), the patient stated he was finally not embarrassed to go to the beach. According to his satisfaction assessment, he would strongly recommend treatments with the ReFit™ Protocol.

Discussion

Volumetric dermal tissue heating for non-invasive and non-ablative aesthetic skin tightening is being studied and applied clinically worldwide. When evaluating other tissue heating techniques, radiofrequency appears to be the most established and clinically proven (DiFrancesco *et al.*, 2010). The technology has the added advantage of affecting various dermal tissue depths, from the reticular dermis to the hypodermis, by adjusting probe characteristics and treatment parameters.

The special treatment protocol that was developed for this type of cases may also be applied to other cases of excessive weight lost, such as post-pregnancy, post-aesthetic procedures for fat reduction (liposuction, laser-lipolysis, focused ultrasound , etc.) and other techniques. Viora's RF–based system is increasingly being used in combination with these kinds of procedures to smooth and firm the skin. ReFit™ treatments may begin two to four weeks after the procedure and generally involves a series of eight treatments.

For example, Dr. Sandra Tagliollato from Brazil and Dr. Eduardo Krulig from Spain combine laser-lipolysis with ReFit™ in order to reduce volume and external signs of cellulite, and additionally expedite the recovery process post-invasive or semi-invasive procedures. Dr. Sebastian Traynor from Argentina successfully treats his patients after liposuction procedure. Dr. Hector Leal from Mexico uses a FUS device in combination with the ReFit™ protocol, and in his study, showed that one treatment session is sufficient to disrupt fat tissue for the purpose of body contouring, and is a safe, effective and well-tolerated treatment (Leal, 2010).

Summary

The design and specifications of the vacuum-assisted, bi-polar radiofrequency device are within the range of currently cleared aesthetic, non-ablative, radiofrequency systems. Due to the unique CORE™ technology, this system may be adjusted to specific client needs. In this case study, for example, Viora developed a special skin tightening protocol for the larger treatment areas, utilizing the BC applicator, which is typically used for cellulite reduction and volumetric treatments. Moreover, given that the symptoms of this young man also included stretch marks, Viora developed a special combination protocol with the ST applicator in order to achieve focused heating over the singular stria.

In addition to the medical benefits, weight loss has a major influence on improvements in psychosocial functioning. However, as was evident in this case study, occasionally weight loss alone is not enough in order to achieve complete satisfaction. In these cases, ReFit™ treatments for body contouring and skin tightening have a substantial contribution to patients' physical and psychosocial well-being.

References

Arnoczky, SP., & Aksan, A. (2000). Thermal modification of connective tissues: basic science considerations and clinical implications. *J Am Acad Orthop Surg*, ***8***, *305-313*.

Cohen, M., & Bar-Yosef, U. (2009). CORE™ Technology: Understanding Penetration Depths of Different RF Modes. © *Viora LTD*. (http://shreis.com/ssscyto/research%20papers/Understanding%20RF%20Depth%20of%20Penentration.pdf)

DiFrancesco, M., Park, C., Martin, K.E., Glithero, J., Privitera, S., & Cassidy, B. (2010). Technological Advances in Minimally Invasive Radiofrequency Ablation of Cardiac Tissues. *Innovations*, ***5***, e138-e146.

Leal, H. (2010). Combined Modality of Focused Ultrasound and Radio-Frequency for Non-Invasive Fat Disruption and Body Contouring – Results of a Single Treatment Session. *IMCAS*, Paris.

Light, D., Arvanitis, G.M., Abramson, D., & Glasberg, S.B. (2010).Effect of weight loss after bariatric surgery on skin and the extracellular matrix. *Plast Reconstr Surg*, ***125***, *343-351*.

Sadick, N.S., & Makino, Y. (2004). Selective Electro-thermolysis in Aesthetic Medicine: A Review. *Lasers Surg Med*, ***34***, 91-7.

Sinno, H., Thibaudeau, S., Tahiri, Y., Mok, E., Christodoulou, G., Lessard, L., Williams, B., & Lin, S.J. (2011).Utility Assessment of Body Contouring After Massive Weight Loss. *Aesthetic Plast Surg*, ***13***. [Epub ahead of print].

© 2014 Viora Ltd.